



## TRICUSPID VALVE REPAIR – OUR EARLY EXPERIENCE WITH EDWARDS C-E PHYSIO TRICUSPID ANNULOPLASTY RINGS

<b>Mufti Faisal</b>	Senior Resident, Department of Cardiothoracic and Vascular Surgery, Vardhman Mahavir Medical College and Safdarjung Hospital, New Delhi.
<b>Peeyush Kesharwani</b>	Senior Resident, Department of Cardiothoracic and Vascular Surgery, Vardhman Mahavir Medical College and Safdarjung Hospital, New Delhi.
<b>Ajit Padhy</b>	Associate Professor, Department of Cardiothoracic and Vascular Surgery, Vardhman Mahavir Medical College and Safdarjung Hospital, New Delhi.
<b>Khushwant Popli</b>	Assistant Professor, Department of Cardiothoracic and Vascular Surgery, Vardhman Mahavir Medical College and Safdarjung Hospital, New Delhi.
<b>Anubhav Gupta*</b>	Professor and Head, Department of Cardiothoracic and Vascular Surgery, Vardhman Mahavir Medical College and Safdarjung Hospital, New Delhi. *Corresponding Author
<b>Nootan Hadiya</b>	Senior Resident, Department of Cardiothoracic and Vascular Surgery, Vardhman Mahavir Medical College and Safdarjung Hospital, New Delhi.

**ABSTRACT** **Objectives:** Very few studies can be found in the current literature regarding post-operative outcome of contoured tricuspid annuloplasty rings. The aim of our study was to analyse our early results of tricuspid annuloplasty using contoured annuloplasty rings and to compare Medtronic Contour 3D ring with Edwards C-E Physio Tricuspid ring. **Material and Methods:** A retrospective analysis of our hospital records was done to analyze the outcome of patients who had undergone tricuspid valve repair using contoured annuloplasty rings between June 2021 and January 2022. Post-operative transthoracic echocardiography was done to assess any residual tricuspid regurgitation and patients were clinically assessed using NYHA functional classification. Average duration of follow-up for all patients was  $5.6 \pm 2$  months (3-10). **Results:** We identified 50 patients for the study among which 25 patients had Contour 3D ring implant and 25 patients had Physio Tricuspid ring implant. Average age of the patients was  $32.6 \pm 12$  years. There was significant improvement in NYHA functional class, grade of tricuspid regurgitation and PASP in both groups. However, comparison between Physio Tricuspid ring and Contour 3D ring did not reach any clinical significance. **Conclusion:** Edwards C-E Physio Tricuspid annuloplasty ring has shown promising early results in our study with low rates of recurrent tricuspid regurgitation and significant clinical improvement. The results are comparable with Medtronic Contour 3D ring with no significant difference between the two types of rings. However, the sample size being small and follow-up being short, larger and long-term studies shall follow to confirm the findings of the present study.

**KEYWORDS :** cardiac surgery, functional TR, organic TR, tricuspid valve repair, tricuspid ring-annuloplasty, Physio Tricuspid, Contour 3D

### INTRODUCTION:

Severe tricuspid regurgitation of either a primary or secondary etiology may not improve predictably after treatment of the left-sided valve lesion and reduction of right ventricular afterload; as such, severe tricuspid regurgitation should be addressed as part of the index procedure<sup>[1]</sup>. Mild or moderate degrees of secondary tricuspid regurgitation may progress over time in approximately 25% of patients and result in reduced long-term functional outcome and survival<sup>[1]</sup>. There has been a significant increase in the number of tricuspid valve repairs performed for these indications over the past decade<sup>[1]</sup>.

Suture annuloplasty has become obsolete owing to high recurrence rates and some studies have suggested abandoning such techniques<sup>[2]</sup>. Annuloplasty rings have shown better results as they tend to restore normal annular geometry, improve leaflet coaptation and prevent annular dilatation<sup>[3]</sup>.

Based on echocardiographic, CT (computed tomography) and MRI (magnetic resonance imaging) studies, 3D (3-dimensional) geometry of normal tricuspid valve has been documented which has led to the development of most precise contoured/ remodeling rings. These contoured devices/rings most accurately resemble the healthy human tricuspid annulus<sup>[4]</sup>.

Only a few studies have been conducted to assess the post-operative results of contoured tricuspid annuloplasty rings and no studies to date could be found in the available literature about the outcome of Edwards C-E Physio tricuspid annuloplasty ring (Physio Tricuspid ring). Hence, we took the opportunity to analyze our early results with tricuspid annuloplasty using contoured rings and especially the Physio Tricuspid ring.

### MATERIAL AND METHODS:

A retrospective analysis of hospital records was done at the Department of Cardiothoracic and Vascular Surgery, Vardhman

Mahavir Medical College & Safdarjung Hospital, New Delhi. Patients who had undergone tricuspid valve repair using contoured annuloplasty rings between June 2021 and January 2022 were included in the study and followed-up till June 2022. In the order of admission, 25 patients with Medtronic Contour 3D 690R (Medtronic, Inc. Minneapolis, MN, USA) implant and 25 patients with Carpentier-Edwards Physio Tricuspid Annuloplasty Ring 6200 (Edwards Lifesciences Corp. Irvine, CA 92614, USA) implant were taken up for study. All these patients had undergone tricuspid valve repair irrespective of other cardiac lesions. Case sheets of all patients were screened for assessment of functional status in pre-operative and post-operative period. The Contour 3D ring group was taken as a control against which the Physio Tricuspid ring group was compared.

### Surgical Procedure:

Tricuspid valve repair was performed in patients who reported severe tricuspid regurgitation or moderate tricuspid regurgitation with annular diastolic diameter of  $>40$  mm or tricuspid index  $>21$  mm/m<sup>2</sup> on pre-operative transthoracic echocardiography. All surgeries were performed via median sternotomy using conventional cardiopulmonary bypass and mild hypothermia. Ring sizing was performed using available ring sizers and fixation was done using interrupted 2-0 non-pledgeted Ethibond (Ethicon, Norderstedt, Germany) sutures.

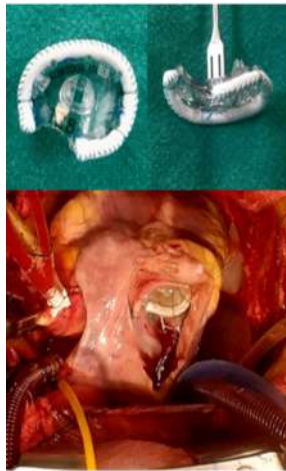### Physio Tricuspid versus Contour 3D Annuloplasty Rings<sup>[4]</sup>:

Both Physio Tricuspid and Contour 3D rings are contoured devices. These devices differ little in their in-plane geometries but vary significantly in their out-of-plane geometries. They most accurately resemble the healthy human tricuspid annulus but differ significantly in bending stiffness. The height of the Physio Tricuspid ring is 3-4 mm depending on size, while the Contour 3D varies between 7-9 mm. Both rings show similar elevation profile with peaks in the anterior-septal and posterior segments of the devices. Curvature profiles of these

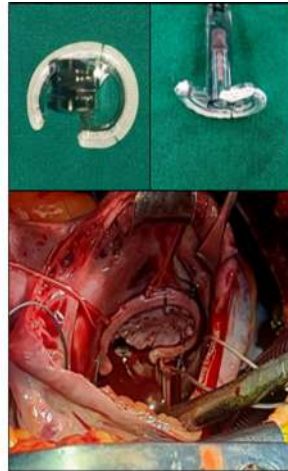
devices are also almost identical but Contour 3D ring is the most curved one due to extreme height profile. The Physio Tricuspid ring is selectively stiff, while the Contour 3D is nearly isotropic. The Contour 3D ring has homogenous bending stiffness along its perimeter, while the Physio Tricuspid ring shows reduced bending stiffness at both ends. The Physio Tricuspid ring is easier to bend up and down and hardest to bend in the in-plane direction, while the Contour 3D device's stiffness marginally depends on which axis it is bent. Figure-1 and Figure-2 show intraoperative pictures of Contour 3D ring and Physio Tricuspid ring.

**Follow-up:**

Patients were either traced from routine OPD (out-patient department) follow-up or telephonically from the mobile numbers provided in the admission papers. Post-operative transthoracic echocardiography was done to assess any residual TR (tricuspid regurgitation) and patients were clinically assessed using NYHA (New York Heart Association) functional classification. TR was graded as 0 (no TR), 1 (mild TR), 2 (moderate TR) and 3 (severe TR). Average duration of follow-up for all patients was 5.6 ± 2 months (3-10). Follow-up was 94% complete till date.



**Figure-1:** Intraoperative images showing Medtronic Contour 3D ring. Image depicting 2-dimensional profile of the ring (1), image depicting 3-dimensional profile of the ring (2) and post implantation image, surgeon's view (3).



**Figure-2:** Intraoperative images showing Edwards Physio Tricuspid ring. Image depicting 2-dimensional profile of the ring (1), image depicting 3-dimensional profile of the ring (2) and post implantation image, surgeon's view (3).

**Statistical Analysis:**

The analysis included profiling of patients on different demographic, clinical and laboratory parameters. Descriptive analysis of quantitative parameters were expressed as means and standard deviation. Categorical data were expressed as absolute number and percentage. Independent Student t-test was used for testing of mean between independent groups. Cross tables were generated and Chi square test was used for testing of associations. *Ap* < 0.05 is considered statistically significant. All analysis was done using SPSS software, version 24.0.

**RESULTS:**

**Cohort Characteristics:**

Table-1 gives an overview of the characteristics of the whole cohort and Table-2 shows detailed characteristics with sub-group analysis according to the type of ring used.

In the Contour 3D group, 11 patients (44%) were males and 14 patients (56%) were females. The mean age of the patients was 33.3 ± 13 years (range: 15-60). RHD (rheumatic heart disease) was the primary pathology in 21 out of 25 patients (84%). 5 patients (20%) had organic tricuspid valve disease while 20 patients (80%) had functional tricuspid regurgitation. 96% of patients had undergone left-side valve procedures in addition to tricuspid valve repair and no patient had undergone isolated tricuspid valve repair.

In the Physio Tricuspid group, 8 patients (32%) were males and 17 patients (68%) were females. The mean age of the patients was 31.8 ± 11 years (range: 9-55). RHD was the primary pathology in 19 out of 25 patients (76%). 8 patients (32%) had organic tricuspid valve disease

while 17 patients (68%) had functional tricuspid regurgitation. 84% of patients had undergone left-side valve procedures in addition to tricuspid valve repair and no patient had undergone isolated tricuspid valve repair.

**Table-1: Pre-operative Characteristics Of The Study Group**

<b>Age</b>	<b>32.6 ± 12 years (r: 9-60)</b>
<b>Gender</b>	
Male	19 (38%)
Female	31 (62%)
<b>Etiology of TR</b>	
Functional	37 (74%)
Organic	13 (26%)
<b>NYHA Functional Class</b>	
II	37 (74%)
III	11 (22%)
IV	2 (4%)
<b>Grade of TR</b>	
Severe (3)	30 (60%)
Moderate (2)	20 (40%)

TR: Tricuspid Regurgitation; NYHA: New York Heart Association

**Table-2: Sub-group Analysis Of The Cohort According To The Type Of Ring Used**

Characteristics	Contour 3D Group	Physio Tricuspid Group	p
<b>Age (years)</b>	33.3 ± 13	31.8 ± 11	0.66
<b>Gender</b>			0.38
Male	11 (44%)	8 (32%)	
Female	14 (56%)	17 (68%)	
<b>NYHA Functional Class</b>			0.35
IV	0	2 (8%)	
III	6 (24%)	5 (20%)	
II	19 (76%)	18 (72%)	
<b>Atrial Fibrillation</b>	13 (52%)	12 (48%)	0.77
<b>Etiology of TR</b>			0.33
Functional	20 (80%)	17 (68%)	
Organic	5 (20%)	8 (32%)	
<b>Grade of TR</b>			0.57
3	15 (60%)	17 (68%)	
2	10 (40%)	8 (40%)	
<b>Pathology</b>			
Rheumatic	21 (84%)	19 (76%)	0.48
CAD	1 (4%)	0	0.31
Infective Endocarditis	1 (4%)	1 (4%)	1
Congenital	2 (8%)	3 (12%)	0.63
Myxomatous	0	2 (8%)	0.15
<b>Index Procedure(s)</b>			0.4
MVR	15 (60%)	15 (60%)	
MVR + AVR	5 (20%)	6 (24%)	
MVRe + ASD Closure	1 (4%)	0	
MVRe + AVRe	1 (4%)	0	
ASD Closure	1 (4%)	3 (12%)	
RA Myxoma	0	1 (4%)	
CABG + MVR	2 (8%)	0	
<b>Pre-op LVEF (mean ± SD)</b>	55.6 ± 5 mmHg	56.8 ± 5 mmHg	0.4
<b>Post-op LVEF (mean ± SD)</b>	54.4 ± 4 mmHg	55.4 ± 7 mmHg	0.2
<b>Pre-op PASP (mean ± SD)</b>	65.5 ± 16 mmHg	69.3 ± 22 mmHg	0.4
<b>Post-op PASP (mean ± SD)</b>	41 ± 10 mmHg	44.5 ± 17 mmHg	0.6

NYHA: New York Heart Association; TR: Tricuspid Regurgitation; CAD: Coronary Artery Disease; MVR: Mitral Valve Replacement; MVRe: Mitral Valve Repair; AVR: Aortic Valve Replacement; AVRe: Aortic Valve Repair; ASD: Atrial Septal Defect; RA: Right Atrium; CABG: Coronary Artery Bypass Grafting; LVEF: Left Ventricular Ejection Fraction; PASP: Pulmonary Artery Systolic Pressure; SD: Standard Deviation

**Functional Outcome:**

In the Contour 3D group, pre-operative clinical assessment revealed 19 patients (76%) to be NYHA-II, while 6 patients (24%) were NYHA III or IV. There was significant improvement in NYHA class at the last

follow-up with only 2 patients (8%) being categorized NYHA II or more ( $p < 0.001$ ). Atrial fibrillation was found in 13 out of 25 patients (52%). Pre-operative transthoracic echocardiography showed severe tricuspid regurgitation in 15 out of 25 patients (60%) and moderate tricuspid regurgitation in 10 patients (40%). Mean LVEF (left ventricular ejection fraction) was  $55.6 \pm 5$  mmHg and mean PASP (pulmonary artery systolic pressure) was  $65.5 \pm 16$  mmHg. In the immediate post-operative period, there was significant improvement in tricuspid regurgitation ( $p < 0.001$ ) with 5 patients (20%) reporting no tricuspid regurgitation and 20 patients (80%) reporting mild tricuspid regurgitation. At the last follow-up, only 2 patients (8%) reported significant tricuspid regurgitation ( $TR \geq 2$ ). There was significant improvement in PASP with mean PASP of  $41 \pm 10$  mmHg ( $p < 0.01$ ) at the last follow-up. There was no significant impact on left ventricular function with mean post-operative LVEF of  $54.4 \pm 4$  mmHg ( $p = 0.06$ ).

In the Physio Tricuspid group, pre-operative clinical assessment revealed 18 patients (72%) to be NYHA-II, while 7 patients (28%) were NYHA III or IV. There was significant improvement in NYHA class at the last follow-up with only 1 patient (4%) being categorized NYHA II or more ( $p < 0.001$ ). Atrial fibrillation was found in 12 out of 25 patients (48%). Pre-operative transthoracic echocardiography showed severe tricuspid regurgitation in 17 out of 25 patients (68%) and moderate tricuspid regurgitation in 8 patients (32%). Mean LVEF was  $56.8 \pm 5$  mmHg and mean PASP was  $69.3 \pm 22$  mmHg. In the immediate post-operative period, there was significant improvement in tricuspid regurgitation ( $p < 0.001$ ) with 3 patients (12%) reporting no tricuspid regurgitation and 22 patients (88%) reporting mild tricuspid regurgitation. At the last follow-up, only 1 patient (4%) reported significant tricuspid regurgitation ( $TR \geq 2$ ). There was significant improvement in PASP with mean PASP of  $44.5 \pm 17$  mmHg ( $p < 0.001$ ) at the last follow-up. No significant impact on left ventricular function was observed with mean post-operative LVEF of  $55.4 \pm 7$  mmHg ( $p = 0.3$ ).

In total, only 3 patients (6%) reported  $TR \geq 2$  and NYHA  $\geq$  II. Comparison between the competing groups did not reach any clinical significance in terms of improvement in NYHA ( $p > 0.05$ ), tricuspid regurgitation ( $p > 0.05$ ), PASP ( $p > 0.05$ ) and LV function ( $p > 0.05$ ).

3 patients (6%) - 2 (4%) from Physio Tricuspid group and 1 (2%) from Contour 3D group died in late post-op period. Of these 3 patients, only 1 (Physio Tricuspid group) died of cardiac causes. Other 2 patients died due to non-cardiac causes more than 3 months after surgery.

## DISCUSSION:

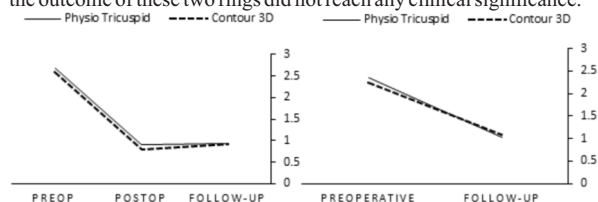
The tricuspid valve annulus has a saddle-like shape which undergoes dynamic changes during various phases of the cardiac cycle. Tricuspid regurgitation, especially the functional one, is caused by annular dilatation and distortion of annular geometry, resulting in disruption of annular dynamics. The premise for tricuspid valve repair was the success of mitral valve repair using annuloplasty rings. Annuloplasty rings tend to restore normal annular geometry, improve leaflet coaptation and prevent annular dilatation. The dynamics of tricuspid valve annulus are very complex and have been studied throughout the cardiac cycle, using echocardiography, CT and MRI. This has led to the evolution of contoured devices which most closely mimic the tricuspid valve annulus.

Earlier, studies had suggested possible resolution of functional tricuspid regurgitation after treatment of primary pathology (e.g., mitral valve replacement) [6], but increasing evidence suggests that some patients may have persistent tricuspid regurgitation or even progression of tricuspid regurgitation causing right heart failure [6-9]. Current ACC/AHA guidelines suggest surgical correction of all severe tricuspid regurgitation and progressive tricuspid regurgitation with annular dilatation of  $>40$  mm (or  $21$  mm/m<sup>2</sup>) or history of prior right heart failure at the time of left sided valve surgery and selected patients with isolated tricuspid regurgitation (either primary tricuspid regurgitation or secondary tricuspid regurgitation attributable to annular dilation in the absence of pulmonary hypertension or dilated cardiomyopathy) [1]. Some studies have suggested persistence, worsening or recurrence of tricuspid regurgitation after suture annuloplasty of tricuspid valve [2]. Many studies have suggested superior results with annuloplasty rings against suture techniques [2,9-14]. However, there are also reports that the rigid annuloplasty rings have higher chances of dehiscence as they do not fit the 3D structure of tricuspid valve annulus [15]. The second generation of rings were flexible but they also essentially freeze the natural dynamics of

tricuspid valve [4]. The third generation of rings are contoured devices, meaning that the elevation, curvature and stiffness of these devices vary along the length of the device. This is to make the contour devices as physiological as possible. Michele De Bonis et al [16], Izutani H et al [17] and Carino D et al [18] have shown good functional outcomes with contoured devices.

The aim of our study was to assess the outcome of Physio Tricuspid ring in our setup and compare it with the established results as well as our own results of Contour 3D ring. This study is the first study from our hospital on tricuspid annuloplasty. The effectiveness of Contour 3D ring is proven in the available literature with many studies showing excellent short-term and long-term outcomes. Carino D et al [18] reported residual or recurrent  $TR \geq 2$  in 13% patients in long term follow-up of 7 years with no difference between Contour 3D and Edwards MC3 rings. Dzilić E et al [19] reported no/trivial or mild TR in 96.1% patients at a mean follow-up of  $2.52 \pm 2.0$  years with Contour 3D ring. Guenzinger R et al [20] reported  $\leq$  mild TR in 94.4% of patients, and 92.0% were in NYHA class I/II at 6 months follow-up with Contour 3D ring. Ratschiller t et al [21] used Contour 3D ring and reported freedom from  $TR \geq 2$  in  $90.9\% \pm 4.2\%$  with no impact on LVEF at a mean follow-up of  $1.0 \pm 0.7$  years. Our results with Contour 3D ring were consistent with the results of these studies in terms of residual or recurrent tricuspid regurgitation ( $TR \geq 2$ : 6%) as well as clinical improvement by NYHA functional class (NYHA  $\geq 2$ : 6%) with no significant difference in the type of ring used. In-hospital mortality and 30-day mortality was nil. 1 death was reported among the Contour 3D group which occurred due to a non-cardiac cause.

There is no study till date in available literature on Edwards Physio Tricuspid ring. Our small cohort showed excellent early results with Physio Tricuspid rings, quite similar to the Contour 3D rings. At a mean follow-up of 5.6 months 96% patients showed no or mild tricuspid regurgitation with only 1 patient (4%) showing moderate tricuspid regurgitation. All patients showed significant clinical improvement ( $p < 0.01$ ). 30-day mortality was nil. However, 2 patients (8%) died in late post-op period among which 1 patient died of cardiac cause and the other one died due to a non-cardiac cause. Comparison of the outcome of these two rings did not reach any clinical significance.



**Figure-3:** A line diagram depicting improvement in tricuspid regurgitation after tricuspid valve repair using Physio Tricuspid ring and Contour 3D ring.

**Figure-4:** A line diagram depicting improvement in NYHA functional class after tricuspid valve repair using Physio Tricuspid and Contour 3D rings; NYHA: New York Heart Association.

## Limitations:

The sample size was small and follow-up relatively short. The study being retrospective in nature could be another limiting factor. All patients who underwent tricuspid valve annuloplasty were studied irrespective of the underlying condition or various patient characteristics. However, earlier studies have also not considered disease specific outcome or patient characteristics separately.

## CONCLUSION:

Edwards C-E Physio tricuspid annuloplasty ring has shown promising early results in our study with low rates of recurrent tricuspid regurgitation and significant clinical improvement. The results are comparable with Medtronic Contour 3D tricuspid annuloplasty ring with no significant difference between the two types of rings. However, the sample size being small and follow-up being short, larger and long-term studies shall follow to confirm the findings of the present study.

## Declarations:

**Funding:** None

**Conflict of interest:** None declared

**Ethical approval:** Not required

**REFERENCES:**

1. Otto CM, Nishimura RA, Bonow RO, Carabello BA, Erwin JP 3rd, Gentile F et al. 2020 ACC/AHA guideline for the management of patients with valvular heart disease: a report of the American College of Cardiology/American Heart Association Joint Committee on Clinical Practice Guidelines. *J Am Coll Cardiol*. 2021; 77: e25–197.
2. McCarthy PM, Bhudia SK, Rajeshwaran J, Hoercher KJ, Lytle BW, Cosgrove DM et al. Tricuspid valve repair: durability and risk factors for failure. *J Thorac Cardiovasc Surg* 2004; 127:674-85.
3. Taramasso M, Vanermen H, Maisano F, Guidotti A, Canna GL, Alfieri O. The growing clinical importance of secondary tricuspid regurgitation. *J Am Coll Cardiol* 2012; 59:703–10.
4. Mrudang M, Marcin M, Tomasz A and Manuel K. Tricuspid annuloplasty rings: A quantitative comparison of size, nonplanar shape and stiffness. *Ann Thorac Surg* 2020; 110:1605-14.
5. Braunwald NS, Ross JJ, Morrow AG. Conservative management of tricuspid regurgitation in patients undergoing mitral valve replacement. *Circulation* 1967; 35:163–9.
6. Anyanwu AC, Chikwe J, Adams DH. Tricuspid valve repair for treatment and prevention of secondary tricuspid regurgitation in patients undergoing mitral valve surgery. *Curr Cardiol Rep* 2008; 10:110–7.
7. Van de Veire NR, Braun J, Delgado V, Versteegh MIM, Dion RA, Klautz RJM et al. Tricuspid annuloplasty prevents right ventricular dilatation and progression of tricuspid regurgitation in patients with tricuspid annular dilatation undergoing mitral valve repair. *J Thorac Cardiovasc Surg* 2011; 141:1431–9.
8. Chikwe J, Itagaki S, Anyanwu A, Adams DH. Impact of concomitant tricuspid annuloplasty on tricuspid regurgitation, right ventricular function, and pulmonary artery hypertension after repair of mitral valve prolapse. *J Am Coll Cardiol* 2015; 65:1931–8.
9. Shinn SH, Dayan V, Schaff HV, Dearani JA, Joyce LD, Lahr B et al. Outcomes of ring versus suture annuloplasty for tricuspid valve repair in patients undergoing mitral valve surgery. *J Thorac Cardiovasc Surg* 2016; 152:406–15. e3.
10. Sohn SH, Kim KH, Lee Y, Choi JW, Hwang HY. Long-term outcomes of rigid ring versus De Vega annuloplasty for functional tricuspid regurgitation: a propensity score-matching analysis. *J Thorac Cardiovasc Surg* 2019.
11. Hirji S, Yazdchi F, Kiehm S, Landino S, McGurk S, Muehlschlegel J et al. Outcomes after tricuspid valve repair with ring versus suture bicuspidization annuloplasty. *Ann Thorac Surg* 2020; 110:821–8.
12. Navia JL, Nowicki ER, Blackstone EH, Brozzi NA, Nento DE, Atik FA et al. Surgical management of secondary tricuspid valve regurgitation: annulus, commissure, or leaflet procedure? *J Thorac Cardiovasc Surg* 2010; 139:1473–82. e5.
13. Tang GHL, David TE, Singh SK, Maganti MD, Armstrong S, Borger MA. Tricuspid valve repair with an annuloplasty ring results in improved long-term outcomes. *Circulation* 2006; 114:1-577–81.
14. Khorsandi M, Banerjee A, Singh H, Srivastava AR. Is a tricuspid annuloplasty ring significantly better than a De Vega's annuloplasty stitch when repairing severe tricuspid regurgitation? *Interact Cardiovasc Thorac Surg*. 2012 Jul; 15(1):129-35.
15. Pfannmuller B, Doenst T, Eberhardt K, Seeburger J, Borger MA, Mohr FW. Increased risk of dehiscence after tricuspid valve repair with rigid annuloplasty rings. *J Thorac Cardiovasc Surg* 2012; 143:1050–5.
16. M De B, Lapenna E, Taramasso M, Manca M, Calabrese MC, Buzzatti N et al. Mid-term results of tricuspid annuloplasty with a three-dimensional remodeling ring. *J Card Surg* 2012; 27:288–94.
17. Izutani H, Nakamura T, Kawachi K. Flexible band versus rigid ring annuloplasty for functional tricuspid regurgitation. *Heart Int* 2010; 5: e13.
18. Carino D, Zancanaro E, Lapenna E, Ruggeri S, Denti P, Iaci G et al. Long-term results of tricuspid annuloplasty with 3-dimensional-shaped rings: effective and durable! *Eur J Cardiothorac Surg* 2021; 60:115–21.
19. Dzilic, E.; Guenther, T.; Bouziani, A.; Voss, B.; Voss, S.; Vitanova, K.; Krane, M.; Lange, R. Results after Repair of Functional Tricuspid Regurgitation with a Three-Dimensional Annuloplasty Ring. *J. Clin. Med.* 2021, 10, 5080
20. Guenzinger R, Lange RS, RieB FC, Hanke T, Bischoff N, Obadia JF et al. Six-Month Performance of a 3-Dimensional Annuloplasty Ring for Repair of Functional Tricuspid Regurgitation. *Thorac Cardiovasc Surg*. 2020 Sep;68(6):478-485.
21. Ratschiller T, Guenther T, Guenzinger R, Noebauer C, Kehl V, Gertler R, Lange R. Early experiences with a new three-dimensional annuloplasty ring for the treatment of functional tricuspid regurgitation. *Ann Thorac Surg*. 2014 Dec;98(6):2039-44.